Feline Alveolar Osteitis Treatment Planning: Implant Protocol with Osseodensification and Early Crown Placement

Abstract

Feline dental implants are becoming a predictable and viable treatment option for the replacement of lost canines due to a painful condition, Maxillary Alveolar Osteitis (AO), commonly experienced by a growing number of cats. Surgical extraction and debridement remains the treatment of choice for this complex inflammatory process. However, future complications can be a common sequelae of maxillary canine removal. This case will demonstrate the successful surgical extraction of a maxillary canine with implant placement, osseodensification protocol, and utilizing the socket osteitis buttressing bone formation to promote a positive result with final crown restoration in 13 weeks.

Introduction

Alveolar Osteitis (AO) is a chronic inflammatory process more often diagnosed in the sockets of the maxillary canine sockets of the feline patient. Clinical presentation may include oral pain, bleeding, periodontitis, tooth resorption (ORL), and alveolar buccal bone changes. (1,2,3,4,5)

Clinical Features:

A presumptive diagnosis of (AO) is made on the awake patient, documenting clinical features such as; Gingivitis with soft tissue swelling, Gingival mucosal erythema, Buccal bone expansion, and Crown extrusion. (Fig 1)

Radiographic Features:

Radiographic changes are identified under general anesthesia. Bony changes and pathology may include; Deep palatal probing (Fig 2a/2b Red) Alveolar bone expansion (Fig 2a Green) Buttressing condensing bone (Fig 2a Blue) Mottled appearance mimicking rough and large trabeculae (Fig 2b Yellow)

Fig. 1 Alveolar Osteitis (AO)

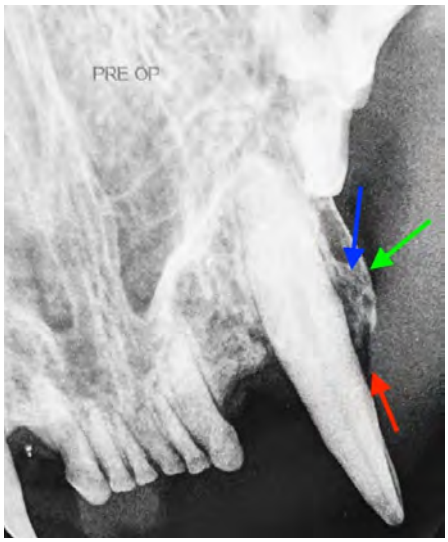

Fig. 2a
Deep Probing (Red)
Bone Expansion (Green)
Condensing Bone (Blue)

Fig.2b
Deep Probing (Red)
Mottled Trabeculae (Yellow)

Osseodensification (OD)

OD is a novel biomechanical bone preparation to place dental implants using Densah burrs which are rotated in reverse mode at 800 to 1500 rpm.
Standard traditional drills remove and excavate bone during implant site preparation. Densah burrs allow bone preservation and condensation through compaction autografting during osteotomy preparation thereby increasing the peri-implant bone density (% BV), and the implant mechanical stability. (6)

Osseous densification was shown to increase the percentage of bone at the implant surface by increasing the bone mineral density in the peri-implant region. Bone compaction has been shown by many studies to improve early fixation stiffness and strength of dental implants. (7,8,9)

Case Presentation:

A 9 year old neutered male DLH cat weighing 5 kg was presented for evaluation of "swollen gums". Initial oral examination noted: (1) Alveolar bone expansion with tooth extrusion (#204). (2) Gingival erythema . (3) Mild tooth mobility (M1). (Fig 1)
A preliminary diagnosis of Alveolar Osteitis (AO) was made. A final diagnosis and treatment plan will be presented to the owner at the time of general anesthesia with a complete oral exam.

Surgical Phase:

At the morning of the scheduled oral surgical procedure, blood was drawn for a complete blood count (CBC) and a diagnostic profile to evaluate the patients general health. Results were all in normal range.

Patient was premeditated with Atropine Sulphate (MWI Veterinary Supply, Boise, Idaho) 0.01 mg/kg subcutaneously (SQ) and Acepromazine Maleate (MWI Veterinary Supply) 0.02 mg/kg SQ. An intravenous catheter was placed and a Lactated Ringers solution was started at a rate of 3 ml/kg/h.

General anesthesia was induced by mask with Sevoflurane (Sevo) (MWI Veterinary Supply). The Sevo Vaporizer was set at #7 and O2 flow was set at 1L. Intubation with a cuffed with endotracheal tube was completed, and the anesthetic agent was maintained at the vaporizer setting of 3%. O2 flow rate was set at 1L / M. A unilateral left maxillary infraorbital nerve block was administered with 0.5% Bupivacaine (Benco Dental, Tucson,AZ) at 0.1ml at the site and Buprenorphine (MWI Veterinary Supply) at 0.01 mg/kg IV followed the General Anesthetic Protocol

Complete oral examination and digital PA radiographs were obtained. Final diagnosis of Alveolar Osteitis was made. The owner was notified of the results and with surgical options available: 1) Surgical extraction (XSS) with socket debridement. 2) XSS with particulate allograft. 3) XSS with possible immediate implant placement. The cats owner chose to place an immediate implant, if possible, and a future restoration.

An envelope flap with a distal vertical releasing incision was designed to expose the underlying bone and to make the removal of the affected canine (#204) less traumatic. Maintenance of the bone and tissue vascularity will make future implant/restoration more predictable. (Fig 3, Envelope Flap / Extraction Site)

Fig. 3
Envelop Flap/Extraction Site

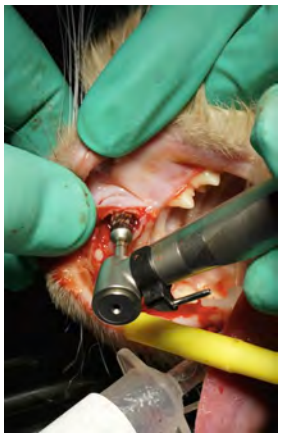

Fig. 4
Densah Burr Osteotomy

Fig.5
Implant Placement

Fig. 6
Bone and Tissue Zone Graft

Fig. 7
Flat Healing Abutment/Prosthetic Seal

Fig. 8
Flap Apposition

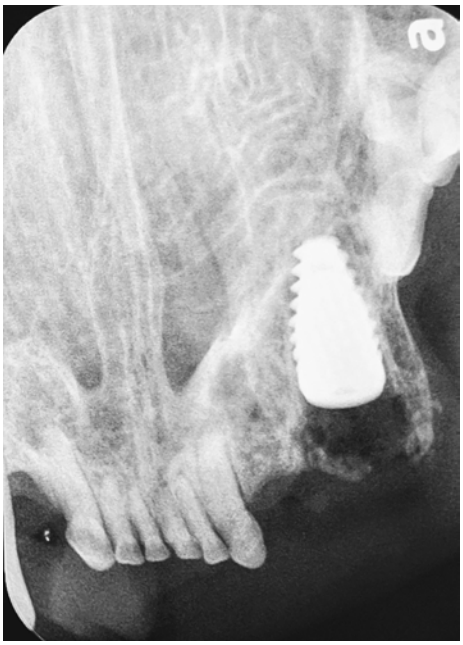

Fig. 9a
Xray Immediate Post-Op

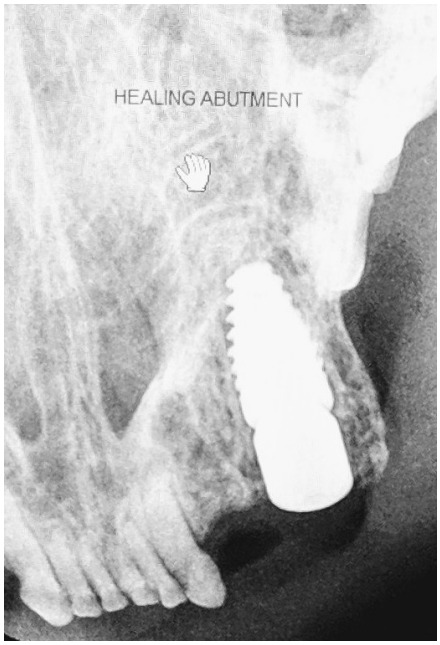

Fig.9b
Xray Immediate Post-Op
HA / Graft

Socket debridement was performed utilizing small curettes and copious lavage with sterile saline. Removal of any connective tissue, bacterial contaminants, and root / bone fragments will ensure a clean interface with the implant and alveolar bone.

Socket osteotomy was accomplished with an osseodensification drilling protocol known as compaction auto-grafting utilizing Densah Burrs (Versah LLC Jackson Michigan) which compress the osteotomized alveolar bone increasing its density to yield better primary stability and superior bone-to-implant contact when the implant is inserted. (Fig. 4 Densah Burr from a similar case).

The burr geometry rotating in reverse mode at a rotary speed of 800 to 1500 rpm with profuse saline solution irrigation to prevent bone over heating, allows to compact the bone along the inner surface of the implant osteotomic site without cutting. The bouncing motion (in and out movement) is helpful to create a rate-dependent stress to produce a rate-dependent strain and allows saline solution pumping to gently pressurize the bone walls. This combination facilitates an increased bone plasticity and bone expansion. (10,11,12,13)

A 5.0mm / 8.0mm OCO engage endosseuos implant was secured to a 4/5mm internal hex driver (OCO Biomedical, Albuqerque, NM) and attached to a Mont Blanc 20:1 implant handpiece. The implant motor was set at 45 Ncm with a speed of 20 rpm. (Aseptico, Woodinville, WA, 98072 USA. The implant was inserted into the condensed site to a depth of 4/5mm sub-crestal (Fig. 5) It torqued out at 45Ncm. The Implant Stability Quotient (ISQ) was 65.

The evolution of Implant Stability Quotient (ISQ) values to access implant secondary stability demonstrated statistically significant correlation with implant outcome. In fact, no implant with > 60 failed, while 19% of implants ISQ < 60 failed. (14)

A cover screw was inserted into the head of the implant. A condenser was utilized to pack an allograft (Veterinary Transplant Service (VTS), Kent, WA) into the gap, filling the bone and tissue zones. Notice, the graft material not only fills the “jump gap” between the implant and bone but occupies the tissue zone to the height of the Free Gingival Margin (FGM). The graft material is incorporated into the tissue zone, acting as a scaffold to support the ridge contour profile and peri-implant tissue. (15) (Fig.6) The screw cap is carefully removed, not to disturb the graft. A 4/5mm flat healing abutment (OCO Biomedical) was placed into the implant acting as a prosthetic seal and tightened with finger pressure with a hand held hex screw driver. (Fig. 7) The flap margins were brought into apposition and closed with Securocryl, a 5/0 synthetic suture material. (Securos Surgical, Fiskdale, Mass.) (Fig.8) Post-Op radiographs were exposed to evaluate implant / abutment interface, and graft placement (Fig. 9a / 9b) Recovery was uneventful and the patient was discharged with post surgical instructions the same day. Cefovecin Sodium was administered SQ at a dose of 0.045 ml/lb (Zoetis,Inc., Kalamazoo, MI 49007) and buprenorphine at a dose of 0.01mg/kg orally every 12 hours for 3/5 days (MWI Veterinary Supply, Boise, Idaho)

Restorative Phase:

Because of the owners busy schedule our re-evaluation was limited to e-mail photos of the surgical site at 3 weeks and 8 weeks post-op. (Fig.10 and 11) The implant site continued to display minimal inflammation with no evidence of mucositis and/or peri implantitis.

Fig. 10
3 Weeks Post-Op

Fig. 11
8 Weeks Post-Op

At 10 weeks post implant placement the patient returned for intra-oral dental radiographs and a final Implant StabilityQuotient (ISQ) value (Osstell USA, Columbia, Maryland) to assess osseointegration for a possible early restoration phase.
The same feline general anesthetic protocol (GAP) for the surgical phase was repeated for the restorative phase. Dental radiographs were exposed demonstrating excellent stability and osseointegration while the ISQ value of 74 was recorded.
ISQ value is an objective world standard for measuring implant stability. The clinical range of ISQ is normally 55-80. With more than 980 scientific references, we know that high stability is greater than 70 ISQ, between 60-69 medium stability, and less than 60 is considered low stability. (14,16)

The Healing abutment (HA) was removed. A 5mm impression coping (OCO Biomedical, Albuquerque, NM) was attached to the implant, (Fig.12) Rostral maxillary and mandibular impressions and bite registry were obtained with Vinyl Polysiloxane (VPS) (Benco Dental, Tucson, AZ) (Fig. 13) The impression coping was then detached and replaced with a new 5mm HA repositioned into the implant maintain the tissue emergence profile (Fig. 14) and a final Xray was exposed (Fig.15)

It is crucial to maintain healthy thick keratinized tissue (KT) around the implant for long term implant and bone stability.
This KT tissue minimizes bone resorption and inflammation around the prosthetics under function. (17,18)

Fig. 12
Impression Coping

Fig. 13
VPS Impressions

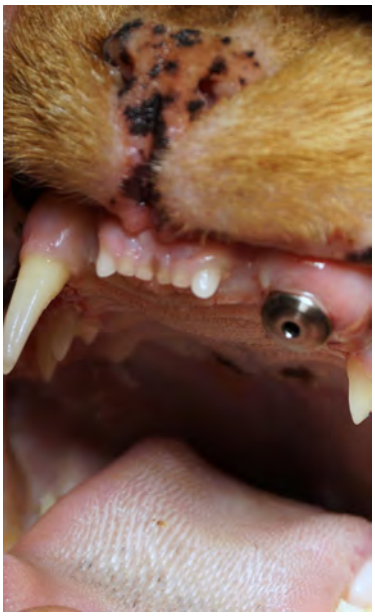

Fig. 14
5mm HA / 10 Weeks

Fig. 15
10 Week Xray / New 5mm HA

Customized Digital Workflow for Veterinary Prosthetics Consists Of:

- Data Acquisitions (Stone Models / 3Shape Scanner)
- CAD (3 Shape Dental Design Software)
- CAM (Substractive Manufacturing-Milling / Sintering)
- Final Veneering (Stain / Glaze)

Impressions are sent to the Dental Lab (Dental Prosthetics. Tucson,AZ.) and a stone model is created with an implant analog within the model and scanned utilizing a 3 Shape D2000 Scanner (3 Shape Inc., Warren, NJ,USA) to create a virtual model (Fig.16/17) Final components are designed incorporating 3 Shape software and CAD CAM milled. (Fig. 18/19)

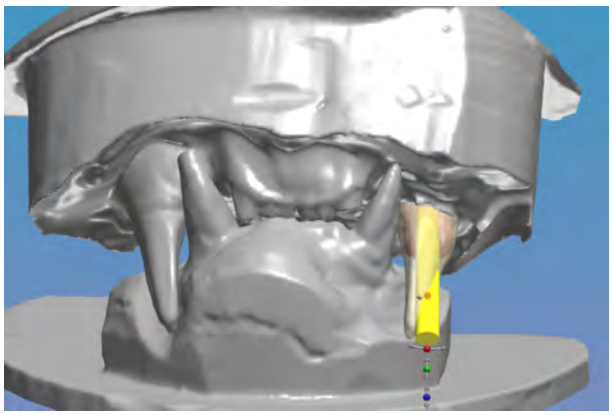

Fig. 16
Virtual Model/Prosthetic Design

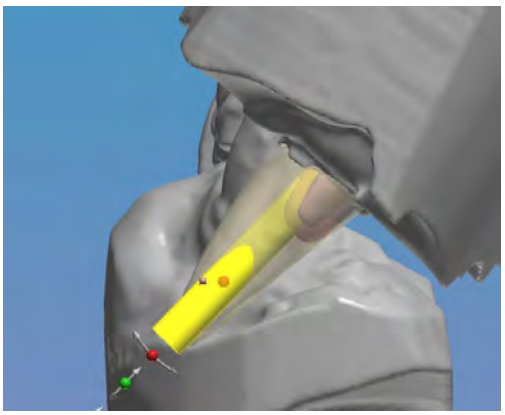

Fig. 17
Virtual Model/Buccal View

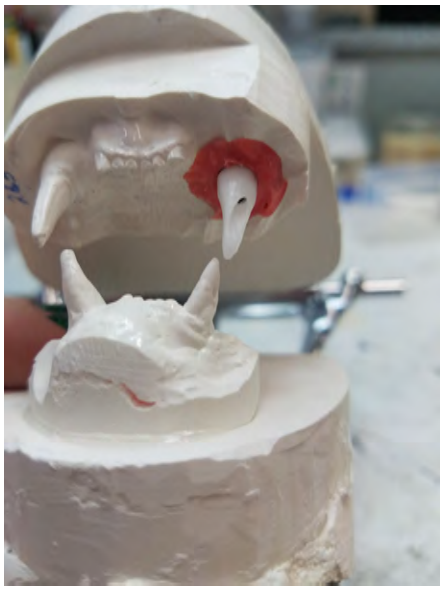

Fig. 18
CAM Milled Crown
Wax

Fig. 19
CAM Milled Crown
Zirconia

Three weeks after the accurate dental impressions were created the patient returned for delivery of the final prosthetic components. (Screw-retained Z Crown / Custom Ti Abutment) The restoration is delivered from the laboratory as a one piece delivery.(Fig. 20, similar case) The patient was anesthetized with the same General Anesthetic protocol followed in the two previous procedures. An oral exam and intra oral radiographs were obtained to evaluate the peri-implant soft tissue and the quality of the bone surrounding the implant. (Fig. 21)

The crown is soaked in chlorhexidine solution for 2 minutes. The prosthetic crown and custom abutments external hex was lined up with the implant platforms internal hex and inserted. An abutment screw is placed into the screw access channel and tightened to 25 Ncm or to the manufactures recommendations. (Fig. 22) The crowns access channel was filled with a light- cured radiopaque, methacrylate-based flowable composite, PermaFlo (Ultradent Products,Inc. South Jordan,UT 84095) (Fig. 23/24)

Fig. 20
Single Unit Crown

Fig. 21
Xray Stable Implant

Fig. 22
Final Single Unit Crown /Screw Access Channel

Fig. 23
Final Composite Restoration-Buccal

Fig. 24
Final Composite Restoration-Occlusal

The nine day and six week re-call appointments display exceptional emergence profile, minimal inflammation, implant stability, and perfect occlusion. The axial contour of the natural tooth or prosthetic crowns as it relates to the adjacent soft tissue, as a good emergence profilers been shown improve the effectiveness of oral hygiene near the gingival sulcus. (19) (Fig. 25, 26, 27)

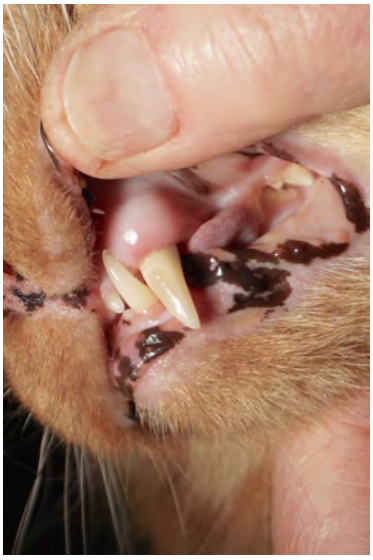

Fig. 25
9 Day Buccal

Fig. 26
9 Day Occlusal

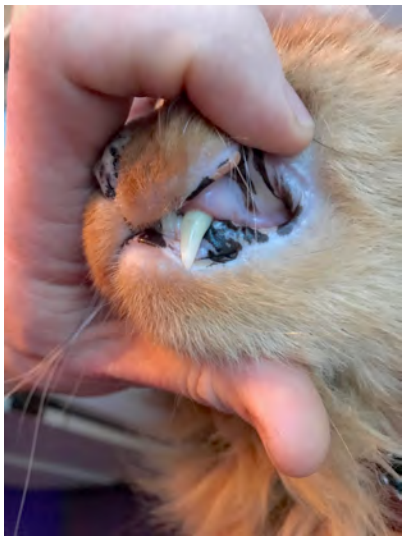

Fig. 27
6 Weeks Buccal

Discussion

Dental implants in the view of many Veterinarians, under no circumstances, should ever be placed in dogs and cats for many reasons including, lack of formal training programs.(20) The authors would agree that formal and rigorous training is necessary to develop acceptable and predictable outcomes. In contrast other disciplines that are universally accepted, such as, endodontics, orthodontics, and periodontics, are continually utilized to save, not extract, functional teeth in our pets. Ironically, the favored argument is that pets do very well without their teeth.

Many years ago there was very little evidence that endodontic and orthodontic treatment was a viable and predictable option for companion animals. Yet, over the years and with a number of published case reports , it has been accepted as a predictable valuable service that can be offered to pet owners in confidence. (21-25)

Until recently there has been no evidence in the literature or any published material that dental implants have ever been applied in specialized treatment planning in canine and feline dentistry. Because clinical case documentation and short and long term follow up is lacking, many would consider this discipline experimental. However, the principal author has placed 50/60 implants in 30/40 feline patients with more than half being restored. All cases have complete documentation with many appearing in multiple publications in Veterinary and Human dental journals.(26-28)

Feline Alveolar Osteitis (AO) is a common presenting problem that the Veterinary Dental Clinician has to deal with routinely. Treatment of this complex condition involves a comprehensive oral exam with dental X-rays under a general anesthetic. Most cases require surgical extraction of the affected tooth, buccal bone osteoplasty, and extensive debridement before a tension free gingival flap is closed. In this case study we explore a paradigm shift in the treatment of AO with surgical extraction, utilizing the alveolar inflammatory changes (bone buttressing) and a revolutionary osteotomy drilling protocol (osseodensification) to develop an ideal site for immediate implant placement, excellent primary stability, and a prosthetic crown restoration in only 13 weeks. This new treatment protocol has proven effective and predictable in over 30 plus cases. Restoration not only provides a normal functioning maxillary canine yet prevents a common complication, lip entrapment, especially in the feline patient.

Customized digital planning is now being utilized in all our implant crown restoration cases compared to older methods of direct wax-ups. With digital planning, the dental laboratory creates a soft tissue model and subsequent castings employing advanced computer-aided design. The computer aided process produces more precise restorative results than the traditional methods of the past.

Detailed post-op instructions for the long term survival of the implant/crown restoration are discussed and sent home with the owner in the departing instructions. Softer food only, no toys, and gentle cleaning of the protheses with soft moist swabs daily for 2/4 weeks. Pain medication and antibiotics are dispensed on case by case evaluation.

Conclusion:

Utilizing the AO inflammatory socket modifications combined with a revolutionary innovative osteotomy technique (osseodensification) we can optimize the surgical site by maintenance of the surrounding bone, soft tissue, and implant stability thus preventing future collapse within the buccal plate.

Immediate implant /restoration can be a manageable approach to restore the feline patient to full function and preclude the serious common complication of feline maxillary canine extraction, lip-entrapment.

References:

1. J Vet Dent. 2008 June 25 (2): 86-95. Significant association between tooth extrusion and tooth resorption in domestic cats. Lewis JR, Okuda A, Shofer FS, Pachtinger G, Harvey CE, Reiter AM

2. Newman MG, Takei HH, Klokkevold PR, Carranza's Clinical Periodontology, 12 th ed. St. Louis Missouri: Sanders; 2015. p. 875

3. Beebe DE, Gengler WR. Osseous surgery to augment treatment of chronic periodontitis of canine teeth in a cat. J Vet Dent. 2007; 24: 30-38 [Pub Med]

4. Periodontology: An overview of alveolar bone expansion. D'Astous J. Can Vet J. 2015 Mar; 56 (3): 295-300

5. Bell CM, Soukup JW, Histological, Clinical, and Radiographic Findings of Alveolar bone expansion and osteomyelitis in the jaws of cats. Veterinary pathology article first published on line: June 25, 2015; Issue published: Sept. 1, 2015, Volume: 52 page (s) 910-918

6. A Novel Osseous Densification approach in Implant Osteotomy Preparation to increase Biomechanical Primary Stability, Bone Mineral Density, and Bone-to-Implant contact. Salah Huwais DDS, Eric G. Meyer PhD. J Oral Maxillofac Implants. 2016: (10 pages). doi: 10. 11607/JOMI. 4817

7. Summers KB, A New concept in Maxillary implant surgery: The osteotome technique. Compendium 1994; 15: 152, 154-162

8. Green JR, Nemzek JA, Arnoczky SP, Johnson LL, Balas MS. The effect of bone composition on early fixation of porous-coated implants. J Arthroplasty 1994; 14: 91-97

9. Kold S, Rihbek O, Vester M, Overgaard S, Soballe K. Bone compaction enhances fixation of weight bearing titanium implants. Clin orthop Relat Res 2005; (431): 138-144

10. Paolo Trisi, PhD,DDS, Marco Bernardini,DDS, Antonello Falco PhD,DDS, and Michelle Podaliri, VMD. New Osseodensification implant site preparation method to increase bone density in low-density bone. In Vitro evaluation in sheep . Implant Dentistry / Volume 25, Number 1 2016.

11. Perren SM, Huggler A, Russenberger M. et al. The reaction of cortical bone to compression. ACTA Orthop Scand Suppl. 1969; 125: 19-29

12. Trisi P, Todisco M, Comsolo U, Travaglini D. High versus low implant torque: A histological, histomorphometric, and bio medical study in sheep mandible. Int J Oral Maxillofac Implants. 2011; 26 (4) : 837-849.

13. Huwais S, Meyer EG. A Novel osseous densification approaching implant osteotomy preparation to increase bio mechanical primary stability, bone mineral density and bone-to- implant contact . Int J Oral Maxillofac Implants. 2017; 32 (1): 27-36

14. Rodrigo D, Aracil L, Martin C, Sans M; Diagnosis of implant stability and its impact on implant survival : A prospective case series study. Clin. Oral Impl, Res 21, 2010; 255-261.

15. Stephen J. Chu, DMD, MSD, CDT; Maurice A. Salama, DMD; Henery Salama, DMD; David Garber, DDS, BDS; Hanae Saito, DDS, MS; Guido O. Sarnachiaro, DDS; and Dennis P. Tarnow DDS. The dual-zone therapeutic concept of managing immediate implant placement and provisional restoration in anterior extractionug 2012 Volume 33 Issue 7.

16. The predictive value of resonance frequency analysis in surgical placement And loading endosseous implants. Serge Baltayan, Joan Pi Anfruns, Tara Aghaloo, Peter Moy. J Oral Maxillofac Surgery 74: 1145-1152, 2016.

17. Rieder C. Customized implant abutment copings to achieve biologic mechanical and esthetic objectives. Int J. Periodont Restorative Dent. 1996; 16 (1) : 20-29.

18. Chiche FA, Leriche MA. Multi-diciplinary implant dentistry for the improved aesthetics and function. Pract Periodontics Aesthetics Dent. 1998 ; 10 (2) : 177-186.

19. Croll BM. Emergence profile in natural tooth contour. Part II : Clinical Considerations . J Prosthet Dent 1990. Apr ; 63 (4) : 374-9.

20. Tannenbaum J, Arzi B, Reiter AM, et al. The case against the use of dental Implants in dogs and cats. J AM Vet Med Assoc. 2013 ; 243 (12) : 1680-1685.

21. Visser C. Endodontology : Chronic Maxillary Sinus abcessation in the Canine. J Vet Dent 1990 : 7 (2) : 12-13.

22. Eisner E. Transcoronal approach for endodontic access to the fourth maxillary premolar in dogs. J Vet Dent. 1990 7 (4) : 22-23.

23. Willams C. Endodontics. Vet Clin North Am Small Anim Pract. 1986 ; 16 (5) : 875-893.

24. Visser C. Coronal access of the canine dentition. J Vet Dent. 1991; 8 (4) : 12-16.

25. Kuntsi-Vaattovaara H, Verstraete F, Kass P. Results of root canal treatment in dogs ; 127 cases (1995-2000). J Am Vet Med Assoc. 2002; 220 (6) 775-780.

26. Mele RE, DVM. Kurtzman G, DDS, Magd, Dicoi. New paradigm shift in Feline Dental Implants in Maxillary Alveolar Osteitis treatment with osseodensification. Spectrum Implants - Spring 2019 - Vol. 10 No 1.

27. Rocco E. Mele, DVM; Anthony Caiafa, BVSc, BDSc, Gregory M. Kurtzman, DDS, MAGD, DICOI. Feline Dental Implants: Long term follow - up of two cases. J Vet Dent 2017, Vol. 34 (4) : 249-258.

28. Rocco E. Mele, DVM, Anthony Caiafa, BVSc, BDSc, Greg Kurtzman, DDS, MAGD, FPFA, FADI, DICOI, DADIA. Dental Implants and Incisor Bridge Placement in a Dog. J Vet Dent. 2016 Vol. 33, (4): 249-258.